

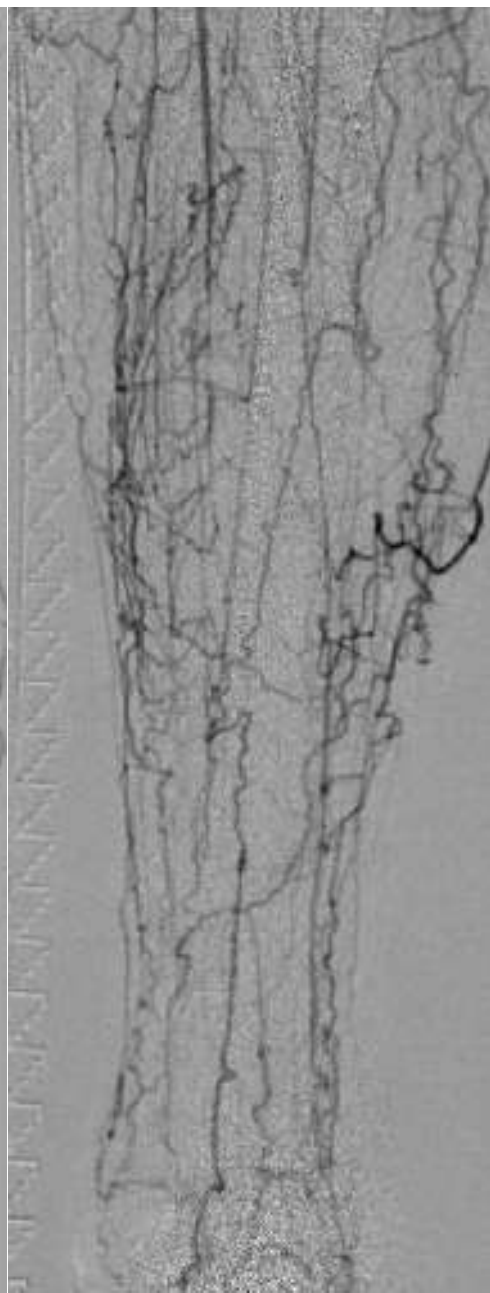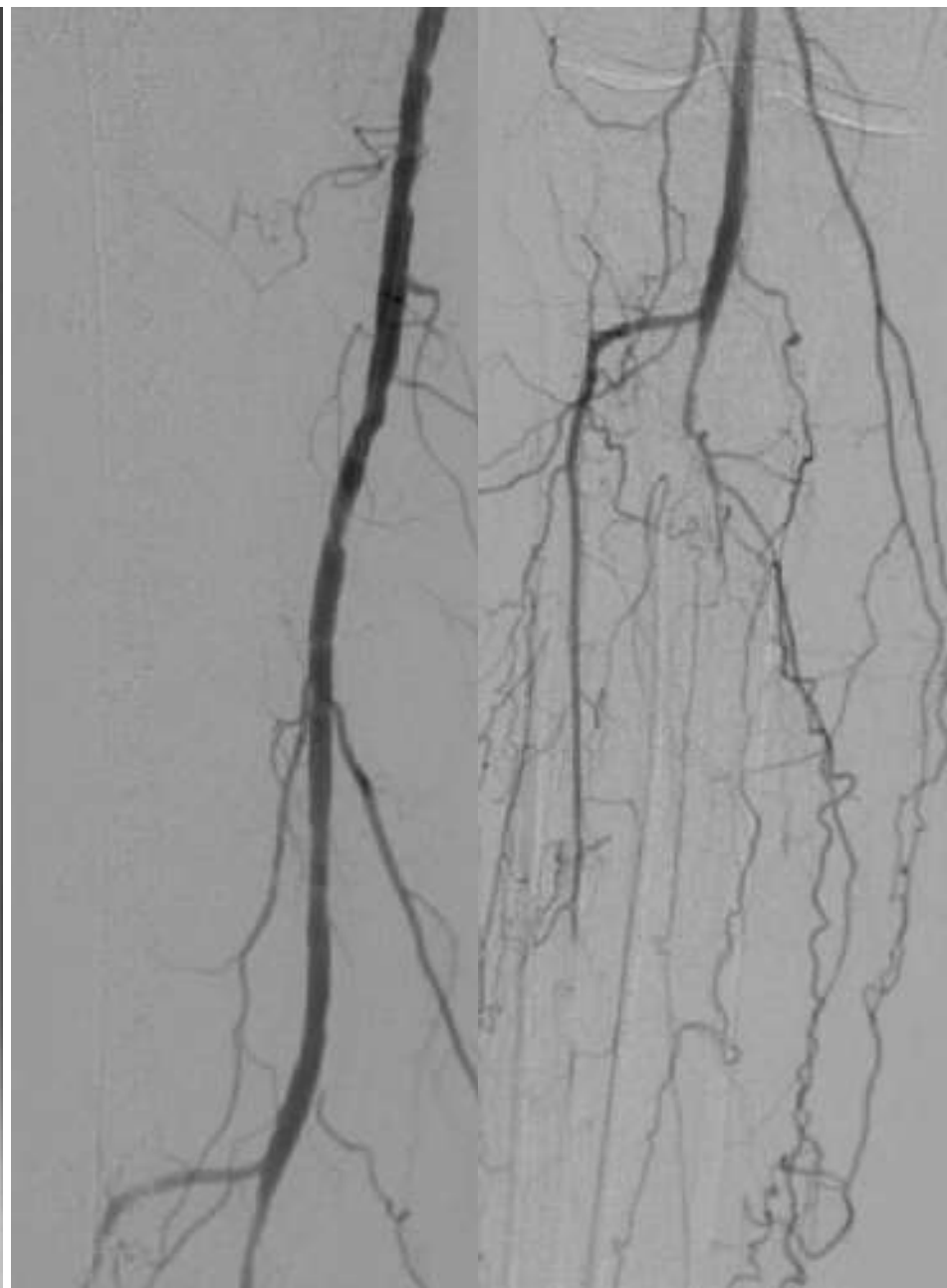
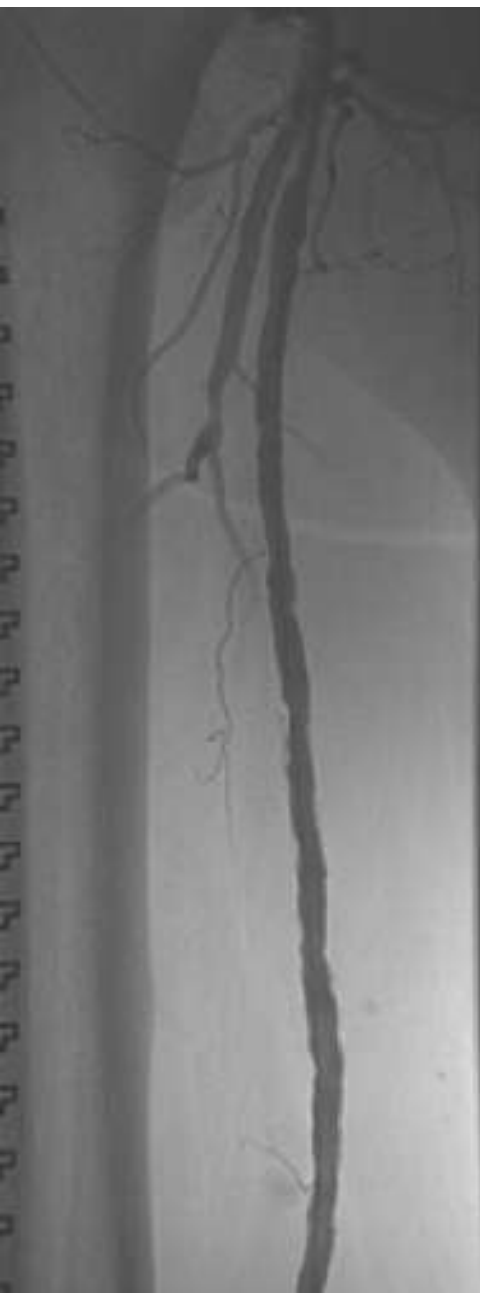J.W., ♂, 76 years

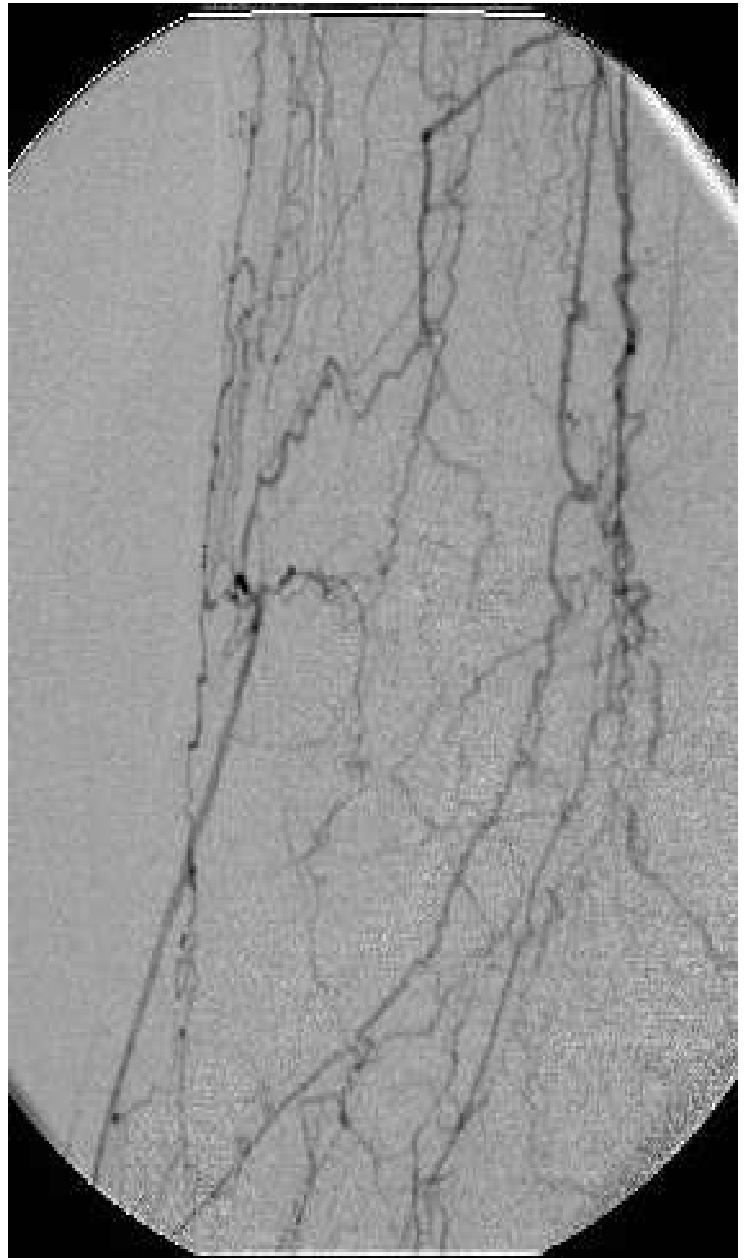
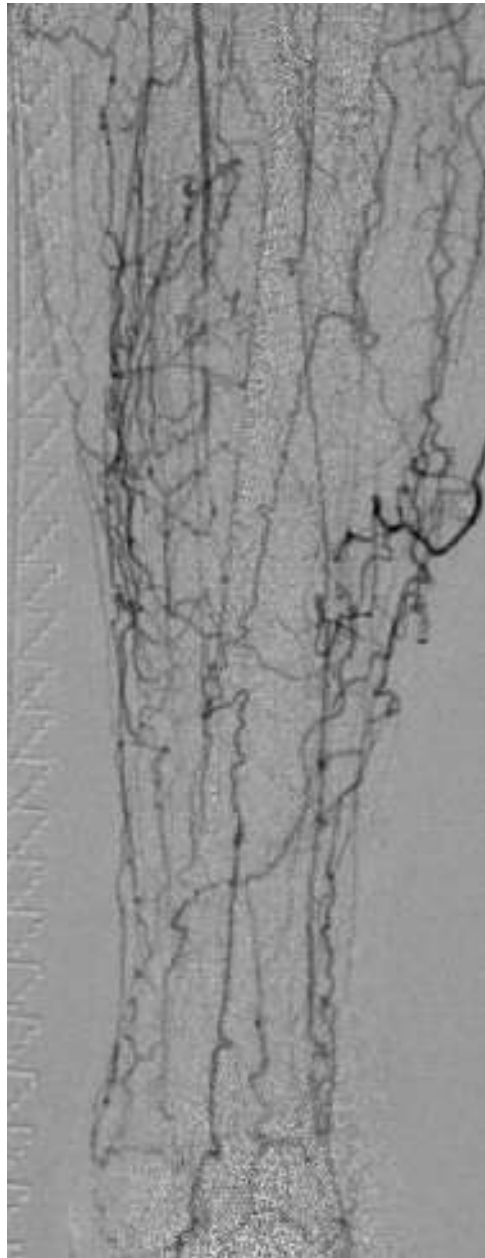
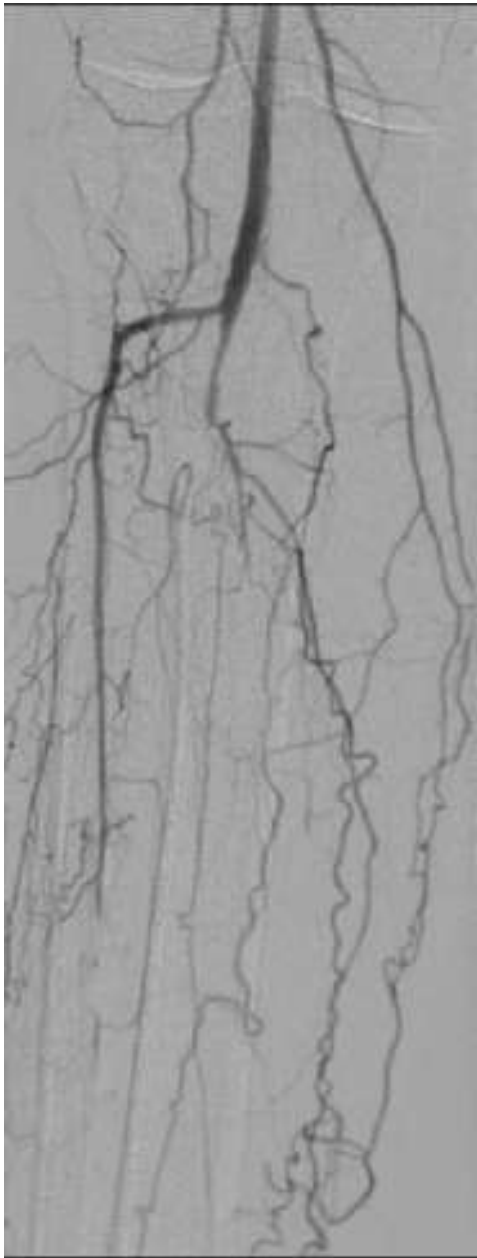
**Clinical data: Previous recurrent MI and CABG 2000,
Stent left common iliac artery 2002
PTA and stent right SFA 1/08 (clinical stage IV)
4/08 : persistent clinical stage IV(Fontaine) right leg,
ulcer big toe**

**Risk factors: Hypertension, Diabetes (Insulin-dependent)
Obesity (172 cm/ 96 kg)**

ABI: Mediasclerosis, Toe pressure :0

**MRA: Moderate stenosis of the infrarenal aorta
Severe macroangiopathy of all lower leg arteries**

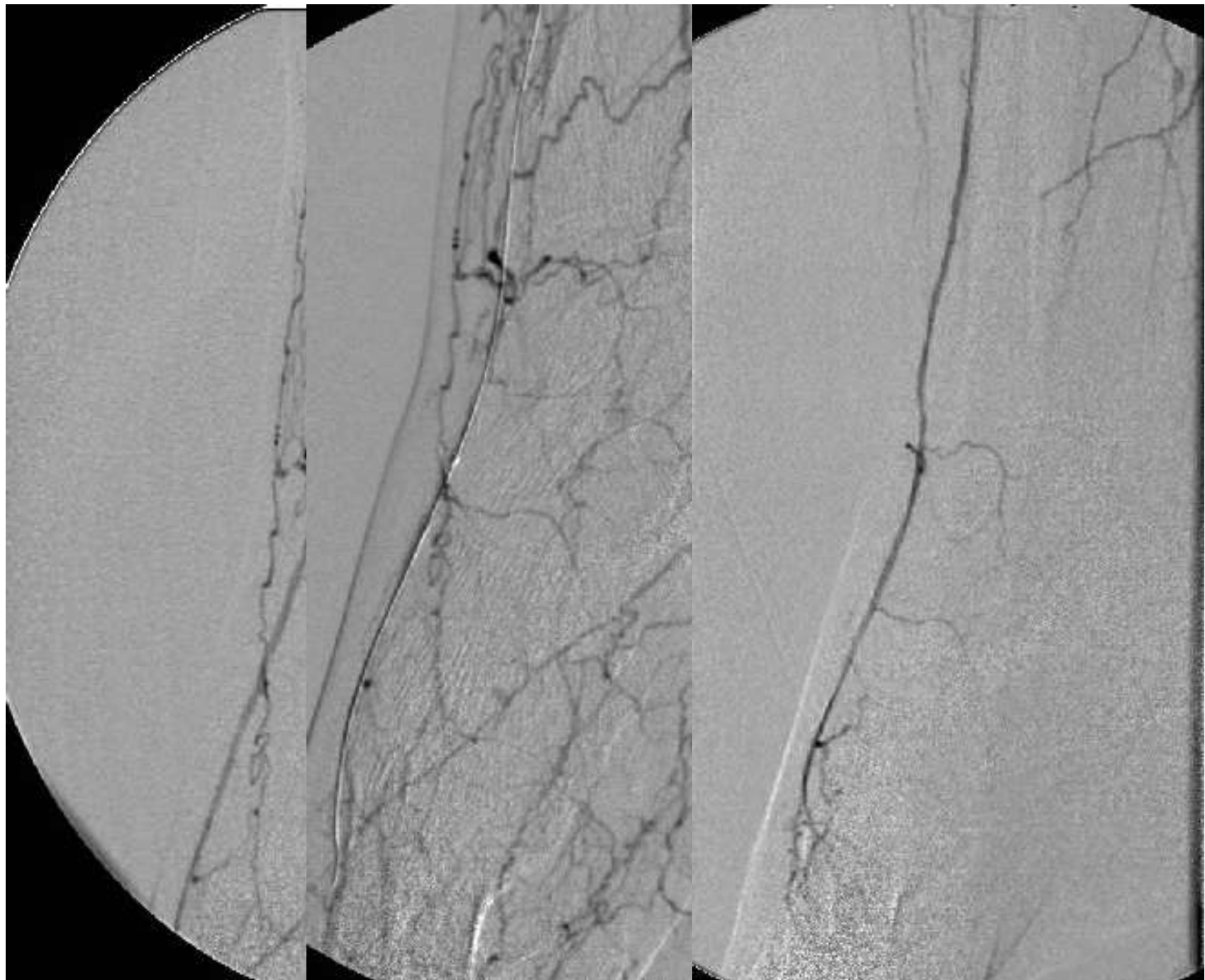




J.W., before PTA

0.018 Control wire

Amphirion Ballon 2.5 mm/ 120 mm



G.O., ♂, 57 years

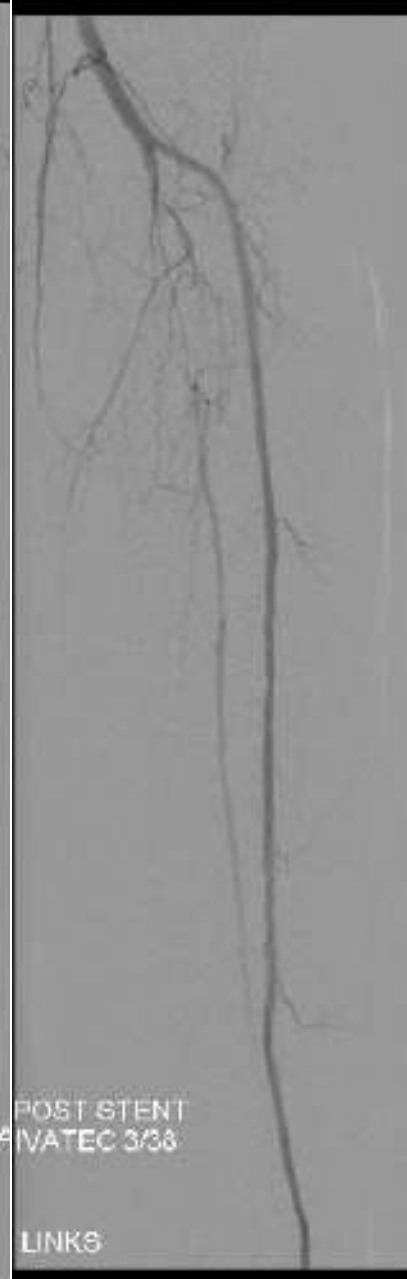
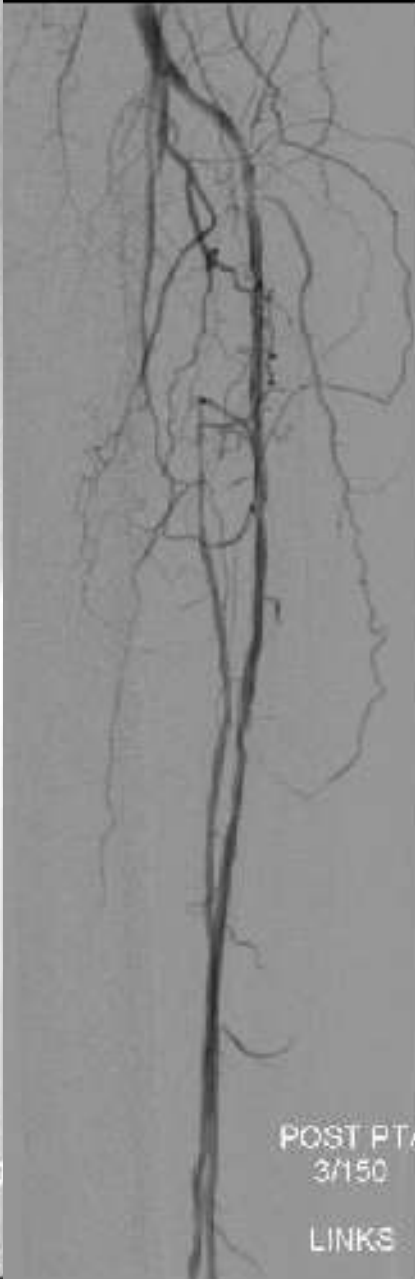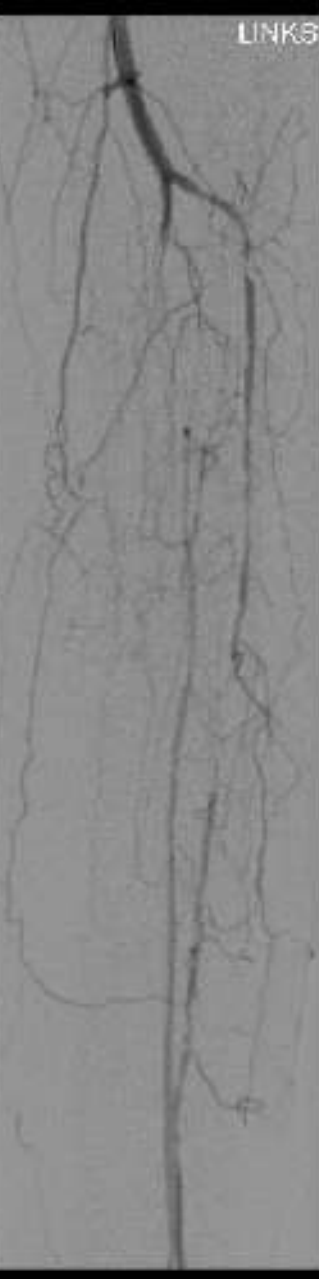**Clinical data: Kidney and pancreas transplantation 10/2005,
3/08 Progressive clinical stage IV left leg**

**Risk factors: Hypertension
Diabetes (Insulin-dependent since 1993)
(Dialysis for 15 months)**

ABI: Mediasclerosis, Toe pressure : <30

MRA: Severe macroangiopathy of all lower leg arteries

•



G.O., before PTA

G.O., after PTA

G.O., after Stent (Chromis deep)